

Thyroid and Parathyroid Ultrasound Protocol

Reviewed By: Anna Ellermeier, MD

Last Reviewed: July 2018

Contact: (866) 761-4200, Option 1

****NOTE for all examinations:**

1. If documenting possible flow in a structure/mass, all color/Doppler should be accompanied by a spectral gate for waveform tracing
****EXCEPTION: Thyroid nodules; spectral tracing does not need to be provided**
2. CINE clips to be labeled:
 - MIDLINE structures: “right to left” when longitudinal and “superior to inferior” when transverse
 - RIGHT/LEFT structures: “lateral to medial” when longitudinal and “superior to inferior” when transverse
 - **each should be 1 sweep, NOT back and forth****

Thyroid

General

-Longitudinal: lateral, mid, medial both lobes

-Transverse: inferior, mid, superior both lobes and isthmus

WHEN & WHAT to CINE:

-If completely normal gland: no CINE is required

-If any part of gland is abnormal:

TRA-MINW

1. Both lobes (even if only 1 is abnormal): Transverse CINE from submandibular gland/hyoid bone to sternal notch through each lobe SEPARATELY
 - If possible, include portion of isthmus on each side
 - If not possible, separate transverse CINE through isthmus
2. ONLY abnormal lobe (s): Longitudinal CINE

Size and Volume:

- Measure size of each lobe and provide volume; provide prior volume if relevant prior is available (if no volume on prior, provide prior measurements)
- Measure thickness (AP) of isthmus on transverse view

Vascularity:

- Representative color Doppler images in longitudinal of each lobe and transverse of isthmus

Nodules:

For reference, ACR TI-RADS Summary Table is attached at the end of this document. This is used by radiologists to describe and categorize nodules and highlights important features to document in nodule imaging.

If measuring a nodule that has been previously biopsied, please provide SIZE (at time of biopsy or immediately preceding formal study), DATE of biopsy and PATHOLOGY results (if available)

For organization:

- Nodules should be labeled, measured and described in the following order to maintain consistency between examinations:
 - 1. Right lobe: superior to inferior
 - 2. Isthmus: right to left
 - 3. Left lobe: superior to inferior

TRA-MINW

-**Label** each nodule on the images to match labels and description on worksheet: Nodule 1 on the images should be same as nodule 1 on the worksheet, Nodule 2 on the images should be same as nodule 2 on the worksheet, etc.

--> Note, in a multinodular gland with nodules in the right, isthmus and left, this may mean that the 1st nodule measured on the left is called "Nodule #4". *Do not start numbers over from #1.*

→ Attempt to re-label nodules the same as prior examinations, i.e.:

-Nodule #4 on examination from 2015 should be labeled Nodule #4 on examination from today

-If Nodule #4 is no longer well seen, document this and continue numbering as per prior examination/worksheet

Document on worksheet: *Location, Size, Basic features (composition, calcifications, margin)*

1. Location:

→ Which side: Right or left lobe

→ Which third: Inferior pole, interpolar, or superior pole

- Which area within this third: Anterior, posterior, medial, lateral, anteromedial, anterolateral, posteromedial, posterolateral

2. **Size** in 3 dimensions: measure in horizontal and vertical (rather than oblique) for consistency across exams

NOTE: Make AP measurement for nodule in the transverse plane on the same image where you measure transverse dimension

3. **DESCRIBE** basic features: composition, calcifications, and margin (in Sonoreview: Select features on worksheet):

1. Composition: solid, cystic/partially cystic or spongiform

-If possible show comet-tail artifact for colloid

2. Echogenic Foci/Calcification: absent or present

-If possible, elaborate as to macrocalcification versus microcalcification

3. Margin: smooth or suspicious

TRA-MINW

-Suspicious = jagged, irregular, portion of nodule extends beyond thyroid, etc.

NOTE: For worksheets, please draw only an oval/circle for the nodule. It is not necessary to detail internal architecture on the diagrams. The legend has been removed for clarity.

Provide adequate images that document nodule vascularity & echogenicity: *Do not need to be described on worksheet by technologist. Radiologist will assess at time of imaging review.*

-Vascularity: Evaluate vascularity of each nodule in real-time.

-Provide: Single color CINE (transverse) through gland.

-->Add more CINEs if gland size warrants to ensure that all nodules are visualized.

-Dedicated color images of each nodule with color are not necessary, EXCEPT:

NOTE EXCEPTIONS:

(1) If there is truly dramatic vascularity of a nodule in real-time: provide short color Doppler of the nodule, CINE if helpful

(2) Cyst: provide single image with color box over anechoic cyst

(3) Vessel: if appears like a hypoechoic nodule or cyst on a still image, provide image with color box to show it is a vessel

-Echogenicity: Provide images that clearly show nodule in relationship to remainder of thyroid and strap muscles

-Technologist does not have to denote echogenicity on worksheet but it *is important to tailor images to help radiologist document accurate echogenicity* (CINEs can help here)

→ For reference:

- Radiologists evaluate echogenicity as it relates to the thyroid gland and the strap muscles. Definitions used by radiologists (per TIRADS document, see table at end of protocol for reference)

TRA-MINW

- Echogenicity = hyper – iso – hypo - VERY hypo
 - Hyperechoic is > thyroid
 - Iso is = thyroid
 - Hypoechoic is < than thyroid but = or > strap muscle
 - VERY hypoechoic is < strap muscle

Guidelines for what to measure:

-Size:

→ SOLID: Measure nodules that are 5 mm or more (in any dimension)

→ CYSTIC/PARTIALLY CYSTIC: Measure nodules that are 1 cm or more (in any direction)

** Smaller nodules (solid < 5mm; cystic/partially cystic < 1cm) do **not** need to be measured or formally recorded on worksheet

- HOWEVER: Please note their presence and general description

→ For example: “multiple small additional solid/cystic nodules bilaterally”

-Multinodular gland: Measure the 3 most suspicious nodules per side and 2 most suspicious in the isthmus

Neck Compartments:

-Evaluate for abnormalities

-Document enlarged lymph nodes: location and size (3 dimensions), comment on presence of calcification

→ Measure 3 largest on each side, if enlarged or abnormal

→ Provide specific images of the central hilum including color Doppler in abnormal lymph nodes

-Accurately mark location of nodes on worksheet

Examples of abnormal nodes:

-Thick, irregular, and/or nodular cortex

TRA-MINW

- Hypervascular cortex
 - Effaced echogenic hilum or non-visualized vascular pedicle
 - Microcalcifications (regardless of size or other morphology)
 - Short axis = or > 10 mm (submandibular: 15 mm), regardless of morphology
 - Anything else deemed worrisome by technologist*
-

Partial or Complete Thyroidectomy

-If available, provide date of surgery, side of malignancy/abnormality and pathology (from Epic, clinic order, etc.)

If partial, follow protocol above for "Thyroid" for the side still present

-Thyroid bed in longitudinal and transverse:

→ Transverse CINE through thyroid bed

→ Transverse CINE out laterally from submandibular gland/hyoid bone to sternal notch

→ Longitudinal CINE through thyroidectomy bed

→ Provide representative images: at least 3 in transverse and 3 in longitudinal

-Any mass or cysts should be measured and documented

Neck Compartments:

-Evaluate for abnormalities

-Document enlarged lymph nodes: location and size (3 dimensions), comment on presence of calcification

→ Measure 3 largest on each side, if enlarged or abnormal (see above)

TRA-MINW

→Provide specific images of the central hilum including color Doppler in abnormal lymph nodes

-Accurately mark location of nodes on worksheet

PARATHYROID

Note: Majority of parathyroid will be next to the thyroid gland, immediately posterior or inferior to the thyroid gland

→Generally hypoechoic to normal thyroid gland with feeding vessel

Representative still and CINE images in longitudinal and transverse images:

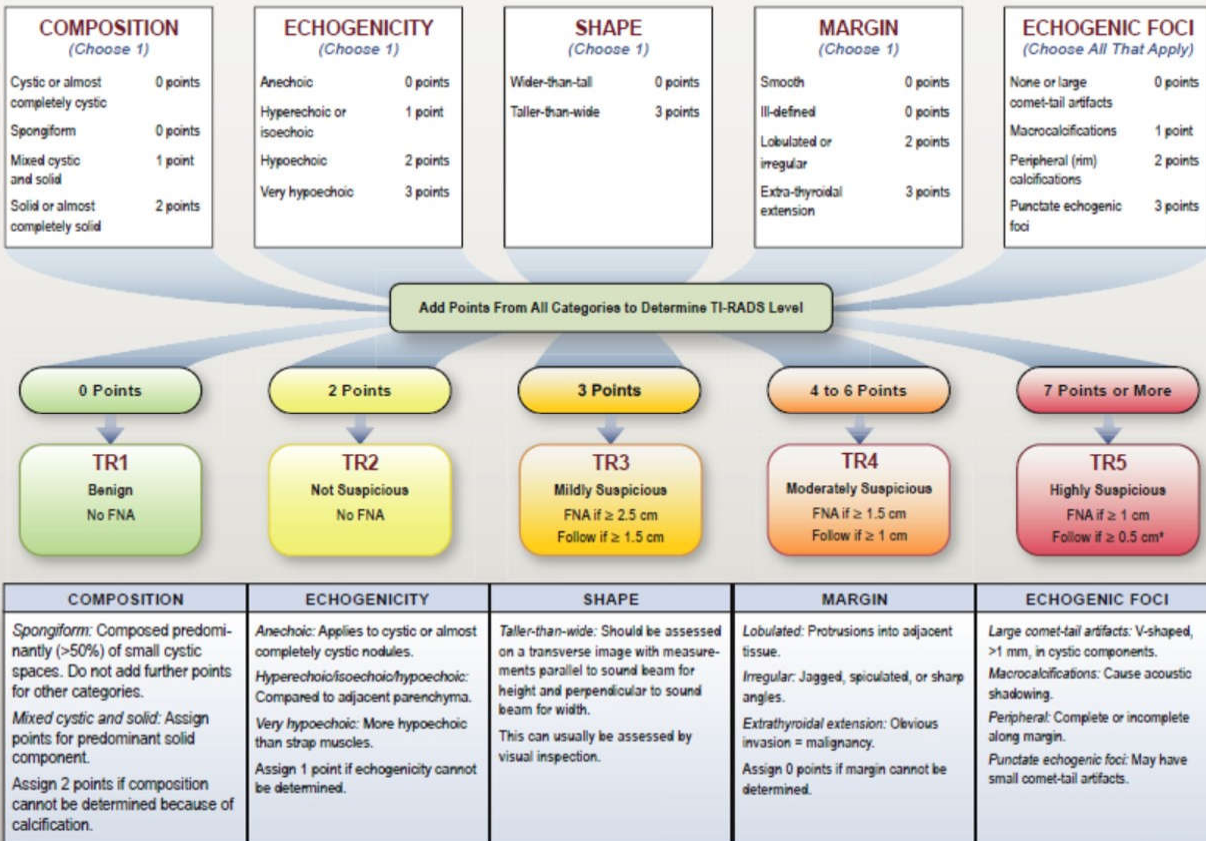
-From carotid artery bifurcation superiorly to thoracic inlet inferiorly: scan through carotid arteries to midline bilaterally

***As parathyroid glands may be hidden below the clavicles in the lower neck and upper mediastinum, it may be helpful to have the patient swallow during the examination with constant real-time observation.*

***Upper mediastinum may be imaged with an appropriate probe by angling under the sternum from the sternal notch.*

TRA-MINW

ACR TI-RADS



*Refer to discussion of papillary microcarcinomas for 5-9 mm TR5 nodules.

J Am Coll Radiol 2017;14:587-595. Copyright © 2017 American College of Radiology